Actual NEU Midterm

➢ Anatomy:

1. The following test is administered to a patient: A cotton applicator is gently applied to the cornea of the eye as the patient is asked to look upward. The patient did not blink in response to stimulation of the cornea. Which cranial nerves are normally involved in this reflex?
   A. Nerves II and III
   B. Nerves III and IV
   C. Nerves III and V
   D. Nerves V and VII
   E. Nerves VII and IX

2. A patient complains that he cannot move his right eye to the right and that the right side of his face is expressionless. The likely locus of the lesion is the:
   A. Dorsal aspect of the medulla
   B. Ventromedial medulla
   C. Dorsal pons
   D. Ventromedial pons
   E. Medial midbrain

3. The patient experiences difficulty in walking down stairs and reports some double vision as well. In this instance, the lesion is most likely located in the:
   A. Medulla
   B. Dorsal pons
   C. Ventromedial pons
   D. Midbrain
   E. Spinal cord

4. A 40-year-old male who had been suffering from a disorder of unknown origin complains to his physician that he has difficulty in producing a smile from the left side of his face, and that he can't salivate or produce tears from the left eye. Further analysis showed some loss of taste and that the affected muscles were flaccid and the eyelids were open. The preganglionic parasympathetic fibers of this nerve arise from the:
   A. Dorsal motor nucleus of the vagus
   B. Nucleus ambiguous
   C. Inferior salivatory nucleus
   D. Superior salivatory nucleus
   E. Edinger-Westphal nucleus of cranial nerve III

5. A patient displays an ipsilateral paralysis of lateral gaze coupled with a contralateral hemiplegia. A lesion is most likely situated in the:
   A. Ventromedial medulla
   B. Dorsomedial medulla
   C. Ventrocaudal pons
   D. Dorsorostral pons
   E. Ventromedial midbrain

6. Which of the following cranial nerves all carry special visceral afferent fibers?
   A. V, VII, and IX
   B. III, VI, and XII
   C. IX, X, and XI
   D. II, VII, and VIII
   E. I, VII, and IX

7. When a patient is asked to follow an object when it is placed in the right side of his visual field, he is unable to move his right eye either up or down. The lesion is most likely situated in the:
   A. Medulla
   B. Basilar aspect of the pons
   C. Pontine tegmentum
   D. Midbrain
   E. Cerebellum

8. The lesion at B would most likely result in which of the following deficits?
   A. Paralysis of the contralateral limbs
   B. Loss of conscious proprioception of the contralateral side of the body
   C. Nystagmus
   D. Lateral gaze paralysis
   E. Facial paralysis

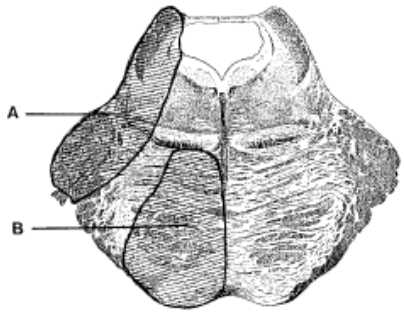

9. Which of the following deficits is likely to occur as a result of the lesion at B?
   A. Contralateral loss of conscious proprioception
   B. Transient tremor of the ipsilateral limb
   C. Ipsilateral fourth-nerve palsy
   D. Hearing loss
   E. Contralateral loss of taste sensation

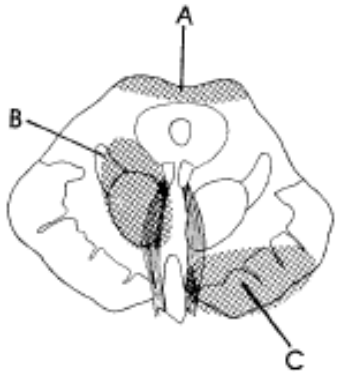

10. A neurological examination of a 75-year-old male reveals that when the abdominal wall is stroked, the muscles of the abdominal wall of the side of the body stimulated failed to contract. Other neurological tests appeared normal. The likely region affected includes:
   A. C1–C5
   B. C6–T1
   C. T2–T7
   D. T8–T12
   E. L1–L5

11. A 55-year-old man discovered that he had pain in the neck and right arm and weakness in extending his fingers of his right hand with loss of sensation in the right thumb and middle fingers. A neurological examination further revealed a weakness of the right biceps reflex, but other neurological signs could not be detected. The most likely diagnosis of this individual is:
    A. Syringomyelia involving the cervical cord
    B. A knife wound of the right arm completely severing nerves innervating the biceps muscle
    C. Prolapse of a cervical disk
    D. Poliomyelitis involving the cervical cord
    E. AIDS

12. Which of the following pathways all cross in the spinal cord?
    A. Lateral spinothalamic tract, anterior spinothalamic tract, posterior spinocerebellar tract
    B. Anterior spinothalamic tract, lateral spinothalamic tract, anterior corticospinal tract
    C. Anterior spinocerebellar tract, posterior spinocerebellar tract, lateral vestibulospinal tract
    D. Anterior corticospinal tract, lateral spinothalamic tract, dorsal columns
    E. Medial vestibulospinal tract, lateral spinothalamic tract, anterior spinothalamic tract

13. An injury to a patient results in a hemisection of the right half of the spinal cord that extends from T8 to T12. It is probable that the patient will experience:
    A. Loss of pain and temperature sensation from the right leg; loss of conscious proprioception from the left leg; UMN paralysis of the left leg
    B. Loss of pain and temperature sensation from the left leg; loss of conscious proprioception from the right leg; UMN paralysis of the left leg
    C. Loss of pain and temperature sensation from the left arm and leg; loss of conscious proprioception from the right leg and arm; flaccid paralysis of the right leg
    D. Loss of pain and temperature sensation from the left leg and loss of conscious proprioception from the right leg; UMN paralysis of the right leg
    E. Bilateral loss of pain and temperature sensation and conscious proprioception, both from the lower half of the body; UMN paralysis of the left leg and flaccid paralysis of the right leg

Read the following scenario and solve questions 14-16.

Gary is a 35-year-old man who was previously healthy until one day, when he noticed that his right leg was weak. As the day progressed, he found that he was dragging the leg behind him when he walked, and he finally asked a friend to drive him home from work because he was unable to lift his right foot up enough to place it on the gas peddle. He also noticed that his left leg felt a little bit numb. Finally, his wife convinced him to go to the emergency room of his local hospital. When Gary arrived at the emergency room, he was having a great deal of difficulty walking. The physician who examined him asked him when this began, and when Gary thought about it in more depth, he realized that perhaps this had started slowly several days before, and he had ignored the symptoms. Gary's language function, cranial nerves, and motor and sensory examinations of his arms were within normal limits. When the physician examined Gary's right leg, it was markedly weak, with very brisk reflexes in the knee and ankle. Vibration and position sense in the right leg were absent. Pain and temperature testing were normal in the right leg, but these sensations were absent on the left leg and abdomen to the level of his umbilicus. Reflexes in the left leg were normal, but when the physician scratched the lateral portion of the plantar surface on the bottom side of Gary's right foot, the great toe moved up. The remainder of Gary's examination was normal.

14. Gary's loss of left-sided pain and temperature sensation could be due to damage to which tract?
    A. Right fasciculus cuneatus
    B. Right fasciculus gracilis
    C. Right spinothalamic tract
    D. Left spinothalamic tract
    E. Left corticospinal tract

15. Why is Gary's right leg weak?
    A. There is muscle damage in the right leg
    B. There is damage in his left frontal lobe
    C. There is damage to the right corticospinal tract
    D. The dorsal root is damaged
    E. There is damage to the right femoral nerve

16. The upward movement of Gary's toe when the plantar surface of his foot was scratched is indicative of a lesion in which portion of the nervous system?
    A. UMN
    B. LMN
    C. Peripheral nerves
    D. Muscles
    E. Sural nerve

17. An elderly female patient complains that she cannot taste the food that she eats. A careful neurological examination reveals no evidence of peripheral damage of the taste receptors. The evidence suggests, instead, that there was selective damage of certain regions of the brainstem. One of the sites where damage could result in the selective loss of taste includes the:
    A. Superior olivary nucleus
    B. Inferior salivatory nucleus
    C. Solitary nucleus
    D. Spinal nucleus of the trigeminal nerve
    E. Reticular tegmental nucleus of the pons

18. A person complains of dysphagia and inability to speak. Upon neurological examination, when the posterior part of the palate was touched, it did not produce any response. Where is the lesion?
    Nucleus ambiguous

19. The parasympathetic ganglion of the glossopharyngeal nerve is?
    Otic ganglion

20. A case where the patient had diplopia, which nerve was affected?
    Trochlear nerve/Midbrain

21. Schwann cells arise from which of the following cells?
    Neural crest

22. Damage to the dorsolateral medulla results in?
    Dysarthria

➢ Physiology:

23. In which of the following points, K+ conductance exceeds the Na+ conductance during a normal action potential?
The choices were combinations of two points

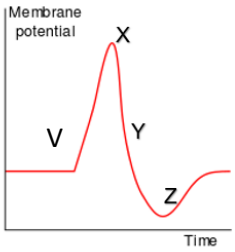

24. Which type of nerve fibers are responsible for transmitting dull, diffuse pain?
C fibers (The question could be the other way)

25. The rate-limiting step in the biosynthesis of catecholamines is
    A. Tryptophan hydroxylase
    B. Tyrosine hydroxylase
    C. Dopamine hydroxylase
    D. Phenylethanolamine-*N*-methyl transferase
    E. Choline acetyltransferase

26. Which of the following is correct?
Alpha motor neurons cause contraction of extrafusal muscles

27. Fast and sharp pain is conducted by which of the following fibers?
A delta fibers

28. Golgi tendon organ detect changes in?
Tension

29. Which of the following about receptors at finger tips is correct?
Fingers are more sensitive than skin on the trunk due to the small receptive field

30. Nociceptors (pain receptors) are sensitive to which of the following?
Tissue damage

31. Which of the following is a fast/the most inhibitory neurotransmitter?
GABA

32. Which of the following factors increases nerve velocity?
Myelination

33. Which of the following tells you that this is an electrical synapse rather than a chemical synapse?
Absence of synaptic delay

34. Degeneration of D2 receptors causes which of the following diseases?
Parkinson's disease

35. Internal opioid substance?
Enkephalin/substance P

36. Break down of glutamate neurotransmitter/ the termination of excess glutamate?
    Na+ dependent cotransporters to astrocytes

37. What happen during the upstroke of the action potential?
    Inward ions influx, cell becomes less negative

38. If another stimulus arrives at A what will happen? No action potential

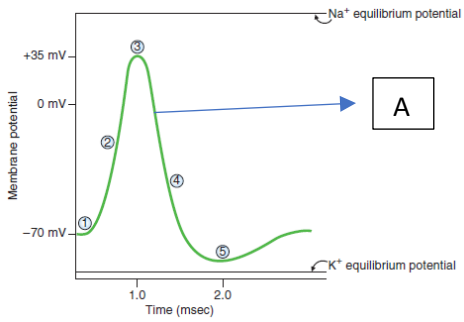

39. Which of the following reflexes indicate stretch reflex?
    Patellar reflex

40. Which sensory receptor is responsible for sensing the slippage of objects along the skin surface, allowing modulation of grip on an object?
    Ruffini corpuscle

41. Which of the following receptors is responsible for light touch and most located in finger tips?
    Meissner's corpuscle

42. A patient has some burns and his extracellular K+ concentration dropped below the normal range, what will happen to the resting membrane potential and the K+ equilibrium potential (EqK)?
    More negative, more negative

43. Closure of metabotropic K+ channel:
    Slow excitatory signals

➢ Pharmacology:

44. Which of the following is the mechanism of action of opioid on postsynaptic neuron?
    K+ channel activation/ potassium efflux

45. Which of the following drugs is used in detoxification therapy for heroin addicts?
    Methadone

46. An unconscious patient presents with respiratory depression and other symptoms. Which of the following signs best indicates the use of opioids/ heroin addiction?
    Meiosis

47. Why are anti-muscarinic agents administered as pre-anesthetic medication prior to surgery?
    Decrease salivary and respiratory secretions

48. Why is epinephrine administered with local anesthetics?
    Prolongs duration of action

49. A patient underwent general anesthesia for surgery purposes. Few days later, he had increased levels of temperature, ALT, AST and bilirubin (signs of hepatotoxicity). Which of the following anesthetic agents was used?
    Halothane

50. In which of the following cases is regional anesthesia used?
    A. Opioid rotation in cancer patients
    B. To relief local back pain
    C. Giving fentanyl via epidural catheter prior to C-section/ post-operative setting

➢ Pathology:

51. Which of the following histopathological pictures indicate Central chromatochemolysis?

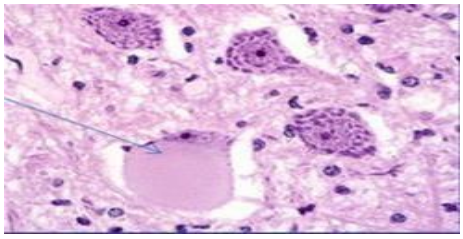

52. Which of the following histopathological pictures indicate axonal spheroids?

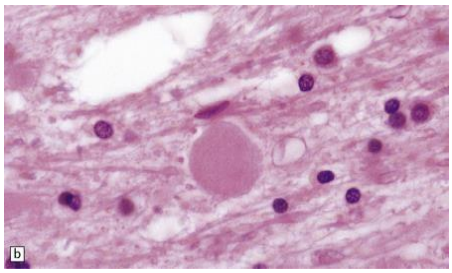

53. Two questions with pictures about different types of herniation. Identify the type. Trans tentorial and subfalcine

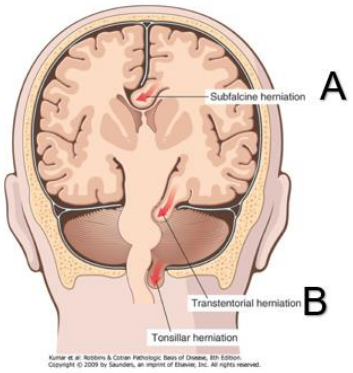

54. A patient experiencing a large pulmonary embolus with severe hypoxia and hypotension. She lived several months following the event, first in coma, then in a vegetative state. What does this image indicate? Global cerebral ischemia

55. What is the clinical presentation of the brain undergoing acute cerebral edema? Flattened gyri, narrowed sulci, compressed ventricular cavities

56. Which of the following glial cells are involved in maintaining the blood brain barrier? Astrocytes

57. What is the most common type of cerebral emboli? Cardiac mural thrombi

58. Identify the brain autopsy. Non-hemorrhagic infarct

Exam questions were collected by exam committee members and other external contributors. This document was compiled, edited and revised by Mariam Hendaz. Don't forget us in your Prayers. Contact me at mhendaz@alfaisal.edu for any concern. ***Best of Luck!***